

Comparison of MRI and CT for the Measurement of Visceral Adipose Tissue

Myeong Seong Kim¹ and Dae Cheol Kweon^{2*}

¹Department of Radiology, The Korean National Cancer Center, Goyang 10408, Republic of Korea

²Department of Radiological Science, College of Bioecological Health, Shinhan University, Uijeongbu 11644, Republic of Korea

(Received 31 January 2019, Received in final form 18 March 2019, Accepted 19 March 2019)

This study aimed to compare the magnetic resonance imaging (MRI) and computed tomography (CT) techniques for the measurement of visceral adipose tissue (VAT). Twenty-five male subjects who underwent CT and MRI imaging within 30 days were included in the study and reviewed by the Institutional Review Board. For MRI, 3.0 Tesla Achieva TX (Philips Medical Systems) was used, and for CT imaging, a 64 channel detector (Lightspeed VCT, Discovery HD 750) was used. VAT was measured at the umbilical level. Cut-off values of Hounsfield units in the range of -50 to -250 were assigned for adipose tissues in the CT images, and the cross-sectional distance ratios were used with MRI scanning. The mean difference in total adipose tissue (TAT) between CT (mean: $21711.7 \pm 5232 \text{ mm}^3$) and MRI (mean $21445.5 \pm 4882 \text{ mm}^3$) was 266 mm^3 . Also, the mean difference in VAT between CT (mean $10133.8 \pm 2304 \text{ mm}^3$) and MRI (mean $10143 \pm 2107 \text{ mm}^3$) was 9.6 mm^3 . The two images were highly correlated with TAT: $R^2 0.90$ ($p < .01$) and VAT: $R^2 0.90$ ($p < .01$). The VAT measured using MRI showed high similarity with the CT image, good reproducibility of soft tissue image, and excellent quantitative value of abdominal obesity.

Keywords : Cross-section, CT, MRI, safety, validation, sequence

1. Introduction

According to the National Health and Nutrition Survey, obesity is increasing in Korea, and diabetes, hypertension, myocardial infarction, as well as many other diseases leading to cancer, are increasing proportionately [1]. Obesity is influenced by daily activities such as diet and exercise. It triggers various adult diseases, and depends on the amount of visceral adipose tissue (VAT) accumulated by hormones like insulin growth factor (IGF) or leptin [2]. The body mass index (BMI), which is commonly used as a measure of obesity, has limitations in assessing the risk of obesity as it has different baseline values depending on race, sex, and age [3, 4].

VAT is a barometer of obesity risk assessment [3, 4]. Although obesity is known to be the most likely cause of metabolic syndrome and cardiovascular diseases, the criteria for determining obesity by measuring the amount of VAT has not yet been clearly defined. Magnetic resonance imaging (MRI), computed tomography (CT) and Dual-X-ray Absorptiometry (DXA) are used for measur-

ing VAT [4, 5]. The most commonly used method in clinical practice is a quantitative measurement of Hounsfield units (HU) on abdominal CT [4-6]. CT uses X-rays and is, thus, dependent on the density of the object to be scanned. However, MRI can accurately express fat and muscle tissue without distorting the three sections (sagittal, coronal, and cross-sectional) [5, 7].

VAT measurement using MRI is comparable to the method based on the fat density [8, 9]. In addition to the software-based fat measurement method, the method using the front-to-back distance on the MRI cross-sectional image, proposed by Qu in 2013, can be said to be based on excellent soft-tissue resolution of MRI [10]. To obtain accurate fat and muscle mass distribution in the human body, CT and MRI cross-sectional images are superior to measurements using other ultrasonic or bioelectric impedance devices [11, 12]. CT images of the abdomen are comparable to MRI, and there is no reason to worry about the side effects of radiation with MRI [10, 11].

The purpose of this study was to compare the VAT using cross-sectional images of subjects who underwent CT and MRI and is not using software in case of MRI.

©The Korean Magnetism Society. All rights reserved.

*Corresponding author: Tel: +82-31-870-3411

Fax: +82-31-870-3419, e-mail: dckweon@shinhan.ac.kr

2. Populations and Methods

2.1. Study Design and Subjects

This study was performed on 25 males who visited a general hospital in the Seoul metropolitan area, between January 2, 2017 and May 31, 2018, and underwent abdominal CT and MRI scan within one month. The mean age of the subjects was 62.5 ± 7.2 years. All CT and MRI protocols were performed in the same manner. Subject recruitment and research was conducted after obtaining approval for the study from the Institutional Review Board (NCC2014-0124).

For MRI, the 3.0 Tesla Achieva TX (Philips Medical Systems, Best, The Netherlands) and a 16-element phased-array surface coil (SENSEXL Torso coil, Philips Healthcare) were used. MRI analysis was performed at the same site as in the CT image (Fig. 1). The parameters used in the MRI scan were TR/TE = 3,500/73 ms. Fat removal was not performed.

To quantify the subject's adipose tissue, all CT and MRI data were transferred to a commercially available workstation computer (Advantage Windows Workstation, version 4.5, GE Healthcare) and then image analysis was obtained the total adipose tissue volume (TAT) from diameter from anterior to posterior and subcutaneous adipose tissue (SAT) from sum of each diameter of anterior and posterior. Thus the percentage of VAT is measured as the ratio of subcutaneous fat to visceral fat in the antero-posterior direction. In other words, the VAT was calculated using the following formula as proposed by Qu in 2013 [10]:

$$\text{VAT}\% = [(\text{AP}-\text{SAT})/\text{AP}] \times 100$$

A: anterior diameter of subcutaneous

P: posterior diameter of subcutaneous

SAT: A + P

AP: anterior-posterior diameter to total transverse length

The detailed measurement is shown in Fig. 1

The CT scanner used was a 64 channel detector (Light-speed VCT, Discovery HD 750; GE Healthcare System, Milwaukee, WI, USA). The parameters used in CT images were 120 kVp, auto exposure control mA (mA range: 100-350), and pitch 1: 1. All CT image analysis was performed the TAT and VAT with CT numbers using HU (-50 ~ -250), which corresponding to CT histogram of adipose tissue at umbilicus level. We measured TAT and VAT not including the SAT using the formula $\text{SAT} = \text{TAT} - \text{VAT}$, and the abdominal obesity rate was calculated using the following formula:

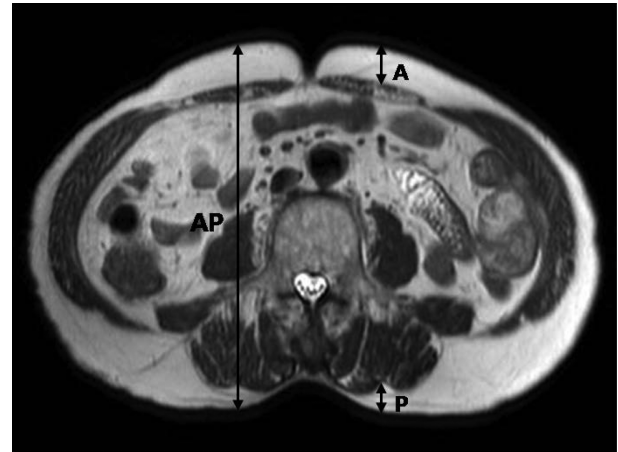


Fig. 1. Measuring distribution of abdominal fat by axial localization. A, P and AP were measured in three images at the umbilical level. A: anterior abdominal fat; AP: antero-posterior diameter; P: posterior abdominal fat.

$$\text{Abdominal obesity rate (\%)} = (\text{VAT} / \text{TAT}) \times 100.$$

The detailed measurement of fat is shown in Fig. 2.

We measured body composition with all modality (CT and MRI) at the same level of umbilicus or the fourth lumbar vertebra, which is a valid method to measure abdominal fat in human [10].

2.2. Statistical Analysis

In order to reduce the error in the measurement of VAT, all the measurements were repeated three times and the mean value was calculated. For comparison of VAT using CT and MRI, SPSS, version 20 (SPSS Inc., Chicago, IL, USA) and Microsoft Excel (Microsoft, Redmond, WA, USA) were used. Bland-Altman analysis was used for the evaluation of VAT, and regression analysis and correlation analysis were used for evaluating the degree of correlation. *P*-value less than 0.05 was considered to indicate statistical significance.

3. Results

The mean TAT / VAT measured on the CT images was $21711.7 \pm 5232 / 10133.8 \pm 2304 \text{ mm}^3$ and the mean TAT / VAT measured on the MRI images was $21445.5 \pm 4882 / 10143 \pm 2107 \text{ mm}^3$. Table 1 compares the distribution of the characteristics of abdominal obesity measured by CT and MRI.

A positive correlation was observed between the results of TAT [$Y = 0.895x + 2013.2$ (R^2 0.91, $p < 0.01$)] and VAT [$Y = 0.871x + 1311.9$ (R^2 0.90, $p < 0.01$)] (Fig. 3). The difference between TAT and VAT was not significant

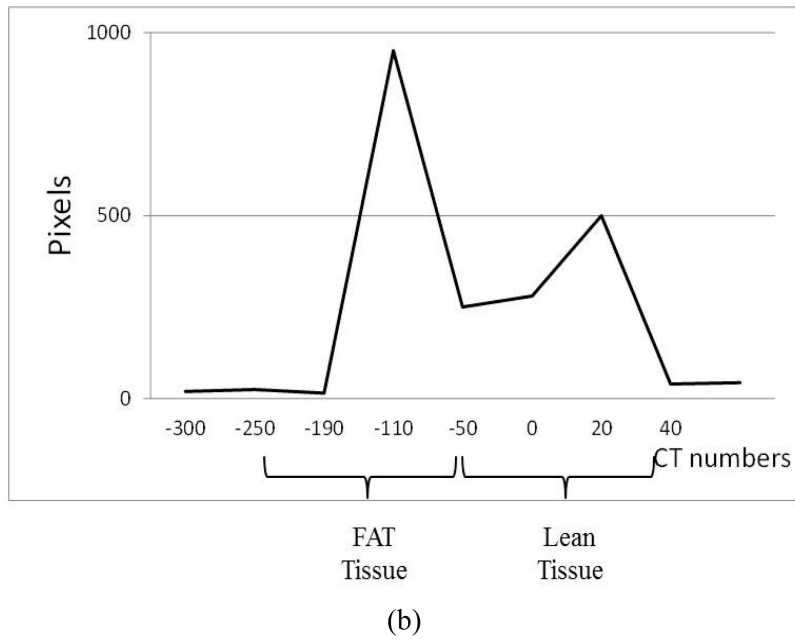
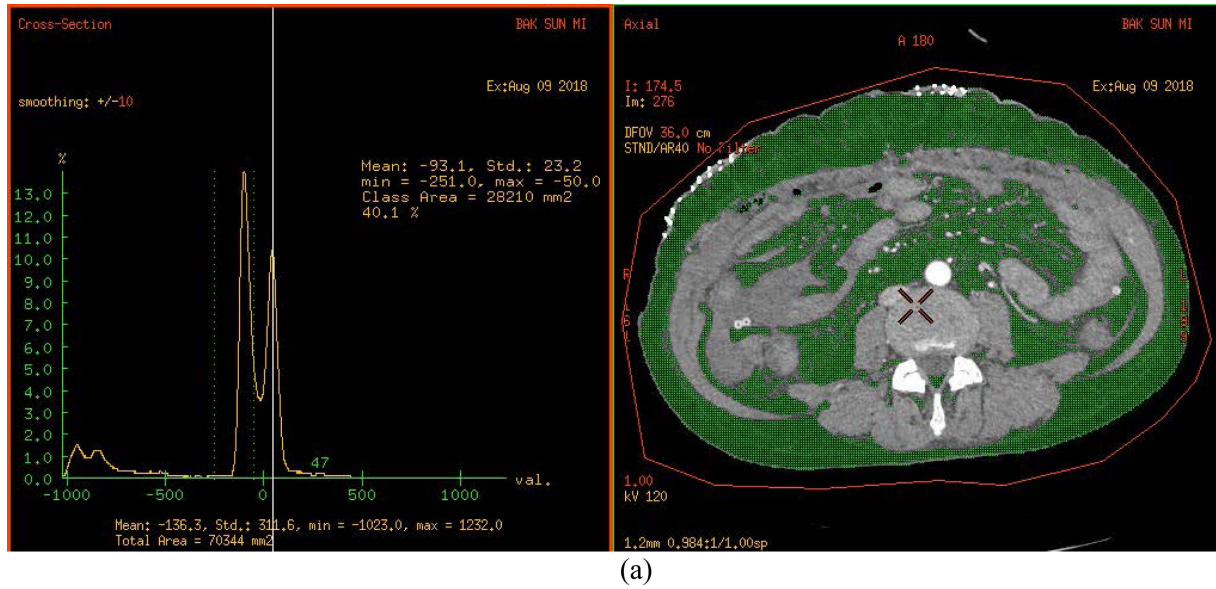

Fig. 2. (Color online) Histogram and measurements of abdominal fat from a CT image at umbilical level. Visceral adipose tissue (shaded) within abdomen (a). Histogram of CT numbers obtained from a CT image (b).

Table 1. Difference in values between MRI and CT.

	Mean difference (mm ³)	Maximum with negative difference (mm ³)	Maximum with positive difference (mm ³)
TAT	266	-360	893
VAT	-9.6	-306	287

(Fig. 3). The one-sample t-test results for the difference between the two methods were 266.4 and 1517.9 ($p = 0.42$) for TAT and -9.6 and 719.8 ($p = 0.42$) for VAT.

Both methods showed statistical similarity in terms of TAT and VAT; however, higher similarity was observed in terms of VAT than TAT.

The distribution of the mean difference between TAT and VAT when two images (CT vs. MRI) were used is depicted in Fig. 4. It shows that the difference between the two methods converges to the average.

4. Discussion

When the average of TAT and VAT measurements

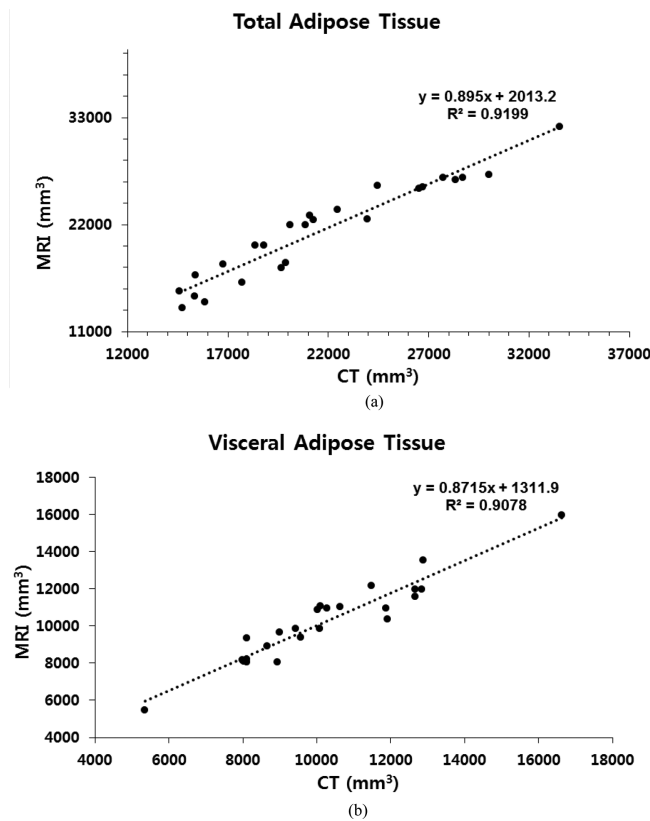


Fig. 3. Adipose tissue areas obtained with MRI compared to those obtained with CT, expressed as percentage of total adipose tissue ($y = 0.895x + 2013.2$; $R^2 = 0.9199$) (a) visceral adipose tissue $y = 0.8715x + 1311.9$; $R^2 = 0.9078$) (b).

determined using CT and MRI were compared, 98.7 % of TAT and 99.2 % of VAT were similar. There are many methods for measuring abdominal fat, however, CT and MRI images have a great advantage due to sectional imaging. In other words, the distribution of muscle mass, visceral fat, and subcutaneous fat in the cross-sectional image of the region of interest can be known accurately. The correlation between VAT and SAT values using CT, MRI was statistically significant. In general, research has shown that waist circumference increases with aging and the amount of visceral fat also increases proportionally [13].

A number of reports state that waist circumference measurements are a convenient way to measure VAT, and waist circumference measurements are similar to abdominal obesity when determined by CT or MRI [13]. However, measurements of waist circumference have different VAT and SAT depending on race, sex, and age. [14]. In order to know the exact VAT and SAT, it is necessary to measure the exact VAT in which the actual obesity hormone is integrated by obtaining a cross-sectional image of the abdominal region (umbilical region

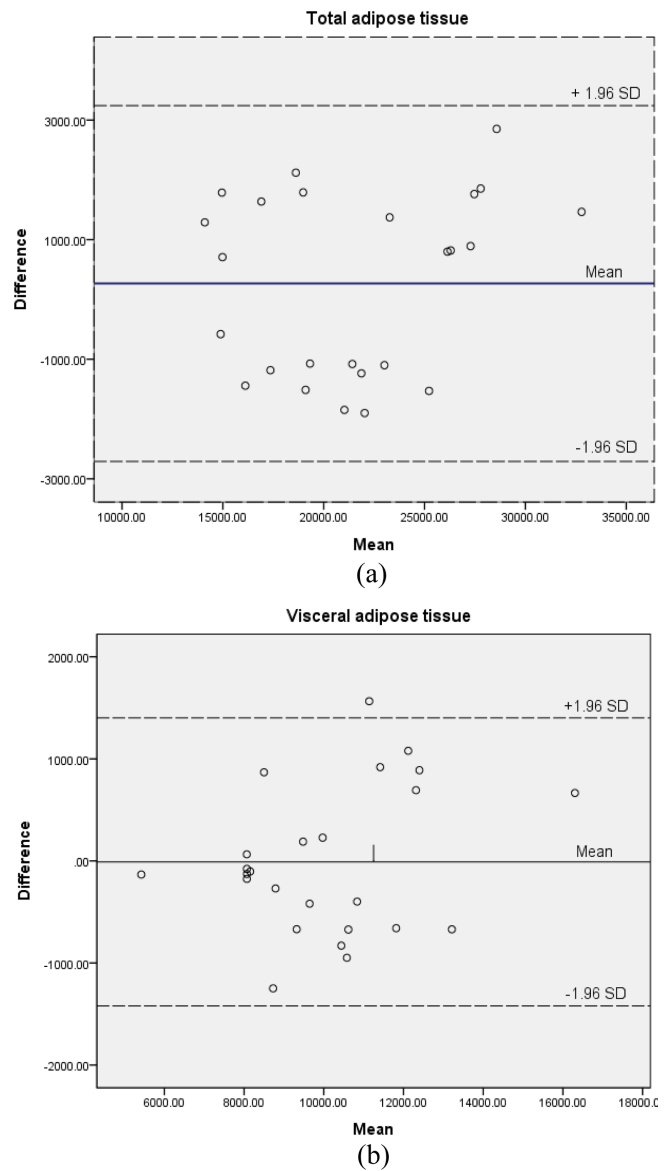


Fig. 4. (Color online) Bland–Altman plots: difference in MRI and CT measured total adipose tissue (TAT) and visceral adipose tissue (VAT).

± 5 cm), such as CT or MRI. In the present study, the TAT and VAT volume comparison using images of CT and MRI were statistically significant (Table 1). The difference between the TAT values measured from CT and MRI was 266 mm^3 , with a maximum difference of 893 mm^3 . In the case of VAT, the mean difference was 9.6 mm^3 , with a maximum difference of 306 mm^3 . The similarity of VAT and TAT using CT images and MRI images were statistically significant.

Most of the current clinical trials, such as those for pulmonary and osteosarcoma, use MRI imaging rather than CT in early diagnosis of cancer. This is because MRI has better tissue resolution than CT. Similarly, MRI can

be used instead of CT to analyze obesity. MRI-based methods for measuring VAT include pixel brightness and global histogram-derived methods, which convert gray scale pixels into binary images using the Image J program's auto threshold plugin (black: fat; white: muscle to blood vessel). There is a series of editing work that divides and cuts VAT and SAT using 3D program.

Previous studies have shown that VAT measured on MRI was lower than that on CT. This is interpreted as a partial volume effect in which SAT is brighter than VAT on the boundary where SAT and VAT are mixed. In this study, the VAT size on MRI images was smaller than SAT compared with CT images.

In this study, the same patient underwent CT and MRI imaging within one month. However, there may be differences in the amount of VAT in the subject at different time points. In addition, although the nerves of the MRI and CT images were measured, there may be differences in the measurement positions, and the selection of the start and end points for MRI may be different. However, since the VAT measurement of CT and MRI images were performed by one person, the inter-observer error was eliminated.

In this paper, the method used to calculate body composition is the distance measurement from anterior to posterior of MR image introduced by Qu in 2013, not using expensive programs. Therefore, it is meaningful for anyone to measure VAT and SAT in MR image easily and compare it with the value measured in CT image which is evaluated as gold standard.

VAT contains tumor necrosis factor- α , interleukin-6, adiponectin, resistin, leptin, and adipsin, which are directly associated with C-reactive protein and cause a variety of chronic diseases such as diabetes, hypertension, and vascular diseases. It is, there, said to act as a reservoir [16, 17]. It is concluded that MRI is more suitable than CT for abdominal obesity analysis because X-ray image representation is effective at higher densities.

5. Conclusion

The similarity between VAT and TAT measurements using CT and MRI images was very high and additional information can be provided by image analysis when conventional CT or MRI examinations are performed. The choice of CT and MRI images to measure abdominal

visceral obesity can be made through the selection of appropriate imaging equipment, taking into consideration the economical and radiation safety of the subject.

References

- [1] W. K. Cho, K. Han, M. B. Ahn, Y. M. Park, M. H. Jung, B. K. Suh, and Y. G. Park, *Diabetes Res. Clin. Pract.* **138**, 169 (2018).
- [2] Y. Matsuzawa, T. Funahashi, and T. Nakamura, *J. Atheroscler. Thromb.* **18**, 629 (2011).
- [3] J. A. Nazare, J. Smith, A. L. Borel, P. Aschner, P. Barter, L. Van Gaal, C. E. Tan, H. U. Wittchen, Y. Matsuzawa, T. Kadowaki, R. Ross, C. Brulle-Wohlhueter, N. Alm eras, S. M. Haffner, B. Balkau, and J. P. Despr es, *Am. J. Cardiol.* **115**, 307 (2015).
- [4] I. Schlecht, B. Fischer, G. Behrens, and M. F. Leitzmann, *Obes. Facts.* **9**, 144 (2016).
- [5] I. J. Neeland, S. M. Grundy, X. Li, B. Adams-Huet, and G. L. Vega, *Nutr. Diabetes.* **18**, e221 (2016).
- [6] Y. J. Choi, Y. K. Seo, E. J. Lee, and Y. S. Chung, *J. Clin. Densitom.* **18**, 192 (2015).
- [7] S. D. Boden, D. O. Davis, T. S. Dina, N. J. Patronas, and S. W. Wiesel, *J. Bone Joint Surg. Am.* **72**, 403 (1990).
- [8] G. Valsamakis, R. Chetty, A. Anwar, A. K. Banerjee, A. Barnett, and S. Kumar, *Diabet Med.* **21**, 1339 (2004).
- [9] K. H. Pietil inen, S. Kaye, A. Karmi, L. Suojanen, A. Rissanen, and K. A. Virtanen, *Br. J. Nutr.* **109**, 1910 (2013).
- [10] Y. Y. Qu, B. Dai, Y. Y. Kong, K. Chang, D. W. Ye, X. D. Yao, S. L. Zhang, H. L. Zhang, and W. Y. Yang, *Asian J. Androl.* **15**, 745 (2013).
- [11] H. Fang, E. Berg, X. Cheng, and W. Shen, *Curr. Opin. Clin. Nutr. Metab. Care.* **21**, 360 (2018).
- [12] A. Andreolia, F. Garaci, F. P. Cafarelli, and G. Guglielmi, *Eur. J. Radiol.* **85**, 1461 (2016).
- [13] G. Valsamakis, R. Chetty, A. Anwar, A. K. Banerjee, A. Barnett, and S. Kumar, *Diabet Med.* **21**, 1339 (2004).
- [14] E. W. Demerath, S. S. Sun, N. Rogers, M. Lee, D. Reed, A. C. Choh, W. Couch, S. A. Czerwinski, W. C. Chumlea, R. M. Siervogel, and B. Towne, *Obesity (Silver Spring)*. **15**, 2984 (2007).
- [15] M. Sezgin and B. Sankur, *J. Electron Imaging.* **13**, 146 (2004).
- [16] I. Kelesidis, T. Kelesidis, and C. S. Mantzoros, *Br. J. Cancer.* **94**, 1221 (2006).
- [17] W. H. Chung, C. T. Kim, I. H. Chang, and S. C. Myung, *Korean J Urol.* **50**, 540 (2009).